



# FOCUSED (Femtosecond Optimized Continuous Uncorrected Sight with EDOF and Diffractive Multifocal IOLs) - A Review

*Brad P. Barnett*

## Purpose of review

The aim of this article is to review techniques to maximize all-distance uncorrected visual acuity and minimize photic phenomena after the implantation of multifocal and extended-depth of focus (EDOF) intraocular lenses (IOLs). This review examines the role of femtosecond laser-assisted cataract surgery (FLACS) in postoperative minimization of astigmatism and optimization of outcomes with multifocal and EDOF lenses.

## Recent findings

By incorporating intraoperative and preoperative imaging, femtosecond platforms such as those that utilize iris or conjunctival vessel registration, can enable a precision of corneal incisions and toric IOL markings that enable the lowest possible postoperative levels of astigmatism. Current studies suggest that with increasing IOL complexity, that is, trifocal versus bifocal, image degradation with even low levels of postoperative astigmatism are increased. To this end, current data support the utility of femtosecond laser arcuate incisions to enable the achievement of 0.5 D or less postoperative astigmatism for best outcomes with multifocal lenses.

## Summary

The synergistic combination of multifocal/EDOF IOLs with FLACS is an extremely promising route in achieving postoperative spectacle independence for patients. The marriage of the precision of FLACS with the increasing complexity of multifocal/EDOF IOLs will fuel nomogram adjustment and systematic improvements, such as the Wörtz–Gupta formula. Such strategies provide an unprecedented precision to cataract surgery that makes FOCUSED (Femtosecond Optimized Continuous Uncorrected Sight with EDOF and Diffractive Multifocal IOLs) a reality.

## Keywords

astigmatism, femtosecond, multifocal, trifocal

## INTRODUCTION

As the most frequently performed surgical procedure, cataract surgery has celebrated numerous incremental and transformative advancements in the past decades. The list of transformative advancements undoubtedly includes Daviel's lens extraction, Ridley's intraocular lens (IOL) implantation, and Kelman's phacoemulsification. In the same way, each of these transformative advancements was met with initial skepticism, yet eventual widespread embrace, it is likely that femtosecond laser-assisted cataract surgery (FLACS) coupled with multifocal and extended-depth of focus (EDOF) IOLs will begin to be understood as a transformative advancement in the field [1–4].

Taken alone, the introduction of FLACS and multifocal or EDOF lenses at first blush may appear incremental. To understand how the marriage of

FLACS and multifocal/EDOF lenses could be transformative, it is important to first acknowledge the state of the art. Currently, patients are presented with three options for glasses after cataract surgery; namely progressive/bifocals, single vision glasses, or no glasses. Couched within this conversation exists numerous caveats. The first caveat for the initial two options is the need for glasses, and in the case of bifocal or single vision lenses, a limited depth of focus. For the third option of spectacle

NVISION Eye Centers, South Sacramento, Sacramento, California, USA

Correspondence to Brad P. Barnett, MD, PhD, NVISION Eye Centers, Sacramento 1220 25th St, Sacramento, CA 95816, USA.

Tel: + 916 306-8123; e-mail: Brad.Barnett@nvisioncenters.com

**Curr Opin Ophthalmol** 2021, 32:3–12

DOI:10.1097/ICU.0000000000000723

## KEY POINTS

- In eyes implanted with multifocal IOLs, uncorrected visual acuity is impaired by residual refractive astigmatism.
- Current data support the utility of femtosecond laser arcuate incisions to enable the achievement of 0.5 D or less postoperative astigmatism for best outcomes with multifocal lenses.
- With increasing IOL complexity, that is, trifocal versus bifocal, the intolerance for residual postoperative astigmatism is increased.
- By incorporating intraoperative and preoperative imaging, femtosecond platforms, such as those that utilize iris registration, can enable a precision of corneal incisions and toric IOL markings that enable the lowest possible postoperative levels of astigmatism.
- Novel formulas, such as the Wörtz–Gupta formula, provide a means of preoperative planning for laser arcuate incisions in patients with low corneal astigmatism ( $<1.0$  D).
- The synergistic combination of multifocal/EDOF IOLs with FLACS provides a level of precision that will enable nomogram adjustment and systematic improvements, making this combination an extremely promising route toward spectacle independence.

independence, the use of EDOF or multifocal IOLs is offered with the caveat of compromised image quality including halos around lights, dysphotopsias, and reduced contrast sensitivity [1–4]. It is the elimination of these caveats that could be the truly transformative aspect of the marriage of FLACS and multifocal/EDOF IOLs.

The literature is replete with examples of FLACS found to be nonsuperior to manual cataract surgery. Moreover, the use of multifocal, and less-so EDOF IOLs, have been plagued with halos, reduced contrast sensitivity, and a variety of visual complaints [1–4]. Although initially largely attributed to personality incompatibilities, calling all engineers and artists, it is becoming increasingly clear that many of these intolerances are actually attributable to uncorrected astigmatism and optical imperfections that may be overcome with the use of FLACS. By enabling precise positioning of the IOL coupled with optical correction, both to the cornea and ultimately the IOL, FLACS with multifocal/EDOF is poised to transform the field of cataract surgery. This review will highlight how the pairing of these two technologies may synergistically enable the transformative advancement of femtosecond optimized continuous uncorrected sight with EDOF and diffractive multifocal IOLs (FOCUSED).

## FEMTOSECOND ASTIGMATIC CORRECTION

Modern refractive cataract surgery increasingly aims to provide enhanced uncorrected vision. In many respects, eliminating astigmatism represents the first barrier to achieve spectacle independence for the majority of patients [1]. At the time of cataract surgery, astigmatism can be addressed numerous ways. Prior to the introduction of toric intraocular lenses, operating on the steep axis, as well as the use of manual corneal arcuate/limbal relaxing incisions, was the mainstay of astigmatism management [1–4]. With the introduction of toric lenses, many groups have achieved good success with monofocal lenses, and in some instances, multifocal lenses without the use of corneal arcuate/limbal relaxing incisions [1–4]. In some instances, providers have adopted the use of nontoric lenses with arcuate incisions for less than 1 D of astigmatism and toric lenses for moderate and high astigmatism. A growing body of evidence is demonstrating that even low-level residual astigmatism is detrimental to image quality in multifocal lenses [1–4]. This decline in image quality and resulting visual acuity is increased with IOL complexity, that is, the trifocal is more compromised than the bifocal multifocal IOL [5<sup>¶</sup>]. As multi-focal IOLs require minimization of astigmatism, FLACS is uniquely suited to optimize postoperative outcomes. FLACS provides image-guided laser incisions in both the cornea and the anterior capsule, to dually reshape the cornea and provide toric alignment markings based upon preoperative corneal analysis and iris registration. Through aiding in precise toric IOL positioning and corneal incisions, FLACS greatest contribution may be in the reduction of astigmatism [6].

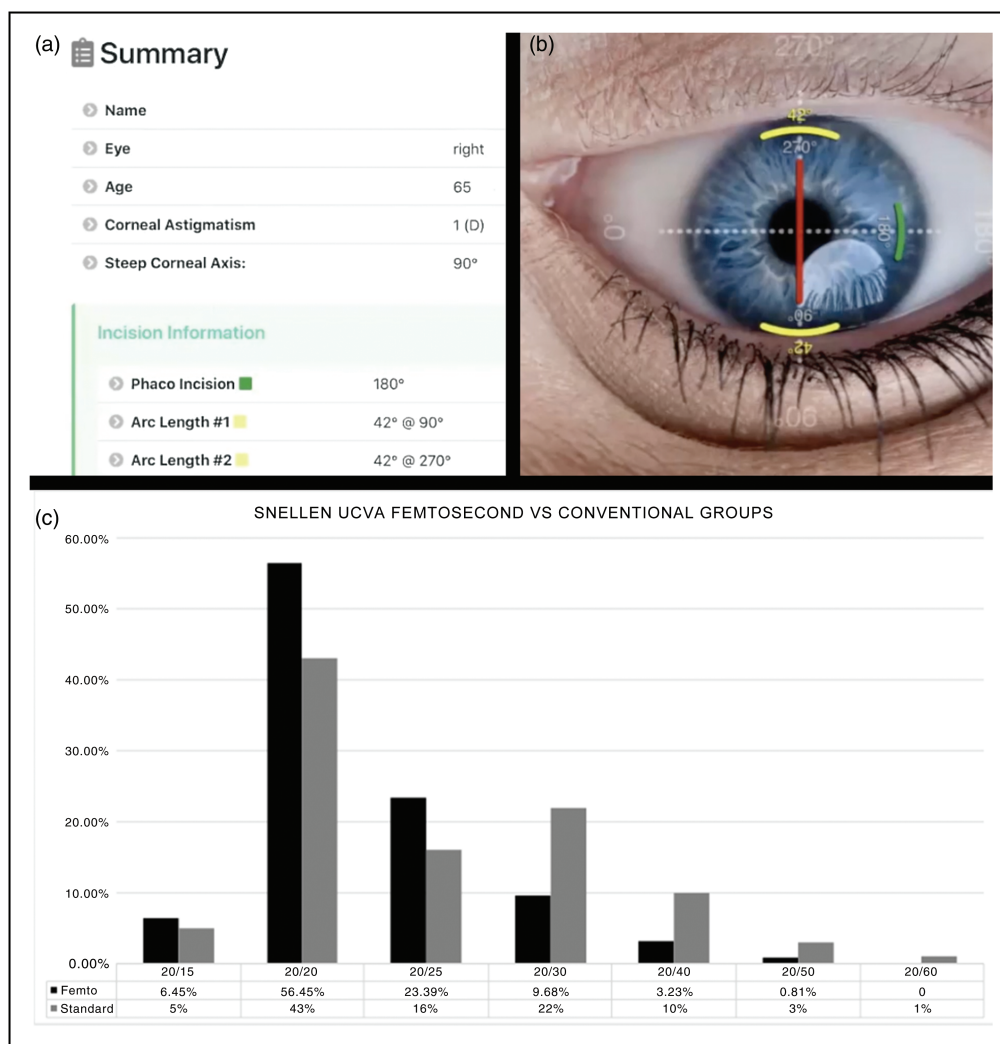
The prevalence of astigmatism is striking. As the most common refractive error worldwide, 75% of patients have more than 0.5 D of astigmatism in one eye and 50% have greater than 1 D of astigmatism in one eye [7]. Another study revealed that 2/3 of cataract surgery candidates have a corneal astigmatism between 0.25 and 1.25 D [1]. Despite this realization, a 2017 survey of ophthalmologists revealed that in 42.8% of cataract patients with at least 1 D of corneal astigmatism, the astigmatism was left untreated [6]. An even greater percentage of patients with less than 1 D of astigmatism is left untreated. The rationale for this is likely two-fold. A certain subset of surgeons is not convinced based upon the current data that treating under 1 D will provide a meaningful benefit to patients. Another subset believes that treating low-level astigmatism is beneficial, however, achieving this goal is elusive. Even in the most skilled hands, uniformly targeting under

1 D of astigmatism with manual incisions and use of toric lenses is challenging.

Corneal arcuate incisions are commonly employed for low levels of astigmatism [4]. With the success of toric IOL correction, many surgeons have begun to use toric lenses in lieu of, instead of in addition to arcuate incisions [8<sup>¶</sup>]. This has resulted in a high percentage of patients with a residual postoperative astigmatism more than 0.5 D [9–16]. In many respects, FLACS has been a hammer looking for a nail. The literature is replete with examples of FLACS being equivalent to manual incision cataract surgery [4,9,17<sup>¶</sup>,18,19]. One area where FLACS demonstrates its superiority over manual is the creation of precise laser arcuate incisions that are superior to manual incisions [9–16]. The inherent requirement of multifocal and EDOF lenses

for nearly absent astigmatism, and the precision by which the femtosecond laser can eliminate astigmatism, may just be the nail FLACS is looking for.

The efficacy of femtosecond laser to treat low-level corneal astigmatism has been demonstrated by numerous groups. A study published by Day *et al.* [16] demonstrated that in eyes undergoing FLACS with intrastromal arcuate incisions, 32% were able to achieve 0.50 D or less of astigmatism postoperatively. Using a modified Nichamin–Woodcock nomogram combined with femtosecond arcuate incisions, Visco *et al.* [8<sup>¶</sup>] were able to achieve 0.50 or less of astigmatism in 95% of eyes. For patients with less than 1 D of preoperative astigmatism, the Wörtz–Gupta formula can guide laser arcuate incisions. Fortunately, the interface for this formula (Fig. 1a and b) is freely available online at



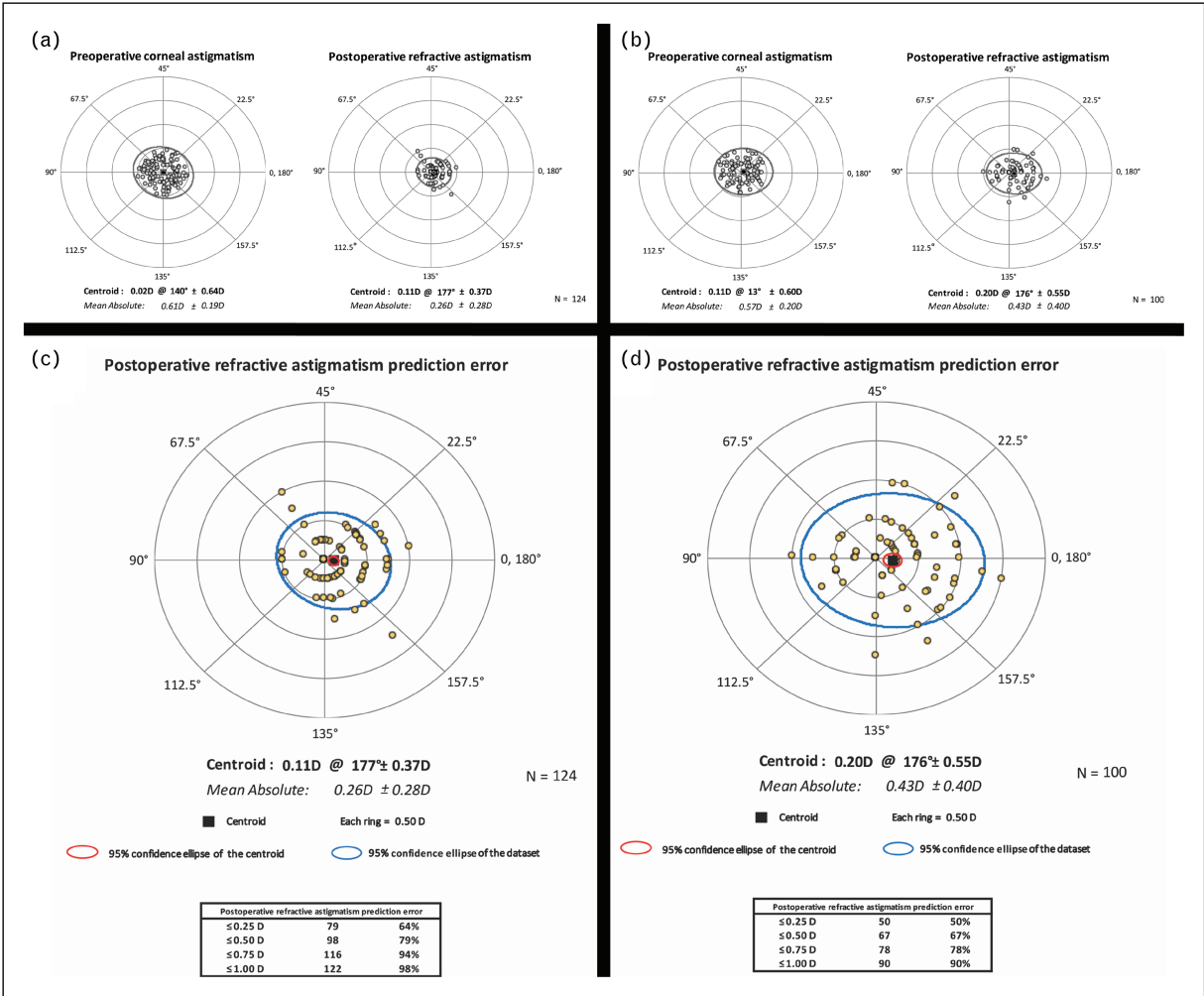
**FIGURE 1.** Astigmatism management with femtosecond laser arcuate incisions in patients with low corneal astigmatism (<1.0D) compared with outcomes after conventional cataract surgery without surgical management of astigmatism. (a) Wörtz–Gupta formula (available at [www.lricalc.com](http://www.lricalc.com)) interface; (b) resulting incisions in lricalc.com interface; (c) postoperative visual acuity in femtosecond laser versus conventional group [20<sup>¶¶</sup>].

<https://lricalc.com>. Utilizing this formula in conjunction with femtosecond laser arcuate incisions in patients with low corneal astigmatism (<1 D), Wortz *et al.* [20<sup>22</sup>] demonstrated superior visual acuity as compared with outcomes after manual cataract surgery without surgical management of astigmatism (Fig. 1c). This is further supported by the resulting double-angle plot for eyes in the femtosecond laser cataract surgery group versus the conventional cataract surgery group (Fig. 2).

Fortunately, based upon data to date, the various femtosecond platforms perform equally well at correcting astigmatism. In a review of the LENSAR system, 94.6–100% of eyes had 0.50 D or less residual refractive astigmatism [8<sup>23</sup>]. This result is comparable to other FLACS with arcuate incisions on other platforms. Using the LenSx laser (Alcon

Laboratories, Inc., Fort Worth, TX, US), Chan *et al.* [9] were able to achieve 0.50 D or less of astigmatism in 50% of eyes postoperatively. The above-mentioned study by Day *et al.* [16] in which 32% of patients achieved 0.5 D or less of astigmatism utilized the Catalys laser system (Johnson & Johnson Vision Care, Santa Ana, CA, US). Another study from Chan *et al.* [9] using the VICTUS laser (Bausch & Lomb, Dornach, Germany), achieved 0.50 D or less residual refractive astigmatism in 33% of eyes.

Although encouraging, the above studies did not result in 0.5 D or less in 100% of eyes. This may be, as Chan *et al.* [9] described, ‘the result of inconsistency in aligning the steepest meridian to the incisions.’ In other instances, the non-insignificant portion of patients with more than 0.5 D of residual astigmatism may be due to the inclusion of patients with more than



**FIGURE 2.** Astigmatism management with femtosecond laser arcuate incisions in patients with low corneal astigmatism (<1.0D) compared with outcomes after conventional cataract surgery without surgical management of astigmatism. Double-angle plot for eyes in the femtosecond laser cataract surgery group (a) and the conventional cataract surgery group (b). Postoperative refractive astigmatism prediction error in femtosecond laser cataract surgery group (c) and the conventional cataract surgery group (d) [20<sup>22</sup>].



2D preexisting corneal astigmatism. This is best demonstrated by Visco *et al.* [8<sup>1</sup>] who demonstrated the most effective range of femtosecond arcuate incisions is for eyes with 0.5 to 2.00 D of preoperative keratometric astigmatism. For patients with more than 2 D of astigmatism, they may be best aided by yet uncreated algorithms that combine toric lenses while also utilizing formulas for optimization of low levels of residual astigmatism such as the Wörtz–Gupta formula for precise femtosecond laser arcuate incisions [20<sup>1</sup>].

To achieve 0.5 D or less of postoperative astigmatism, precise alignment of arcuate incisions and toric IOLs is requisite. With every degree of off-axis correction, there is an estimated 3.3% loss of effect [21]. This off-axis correction induces an entirely new astigmatism and additional higher order aberrations (HOA) [22]. Many of the above-described studies utilized manual marking of the corneal steep axis for the alignment of toric IOLs and femtosecond laser arcuate incisions. In a study utilizing a single manually marked reference point at the temporal limbus, Chan *et al.* [17<sup>1</sup>] acknowledged that, ‘treatment misalignment was a major influential error-inducing factor in astigmatism correction.’ The utilization of automated iris registration coupled with image-guided femtosecond laser corneal incisions shows promise in overcoming the inherent variability introduced with manual marking techniques.

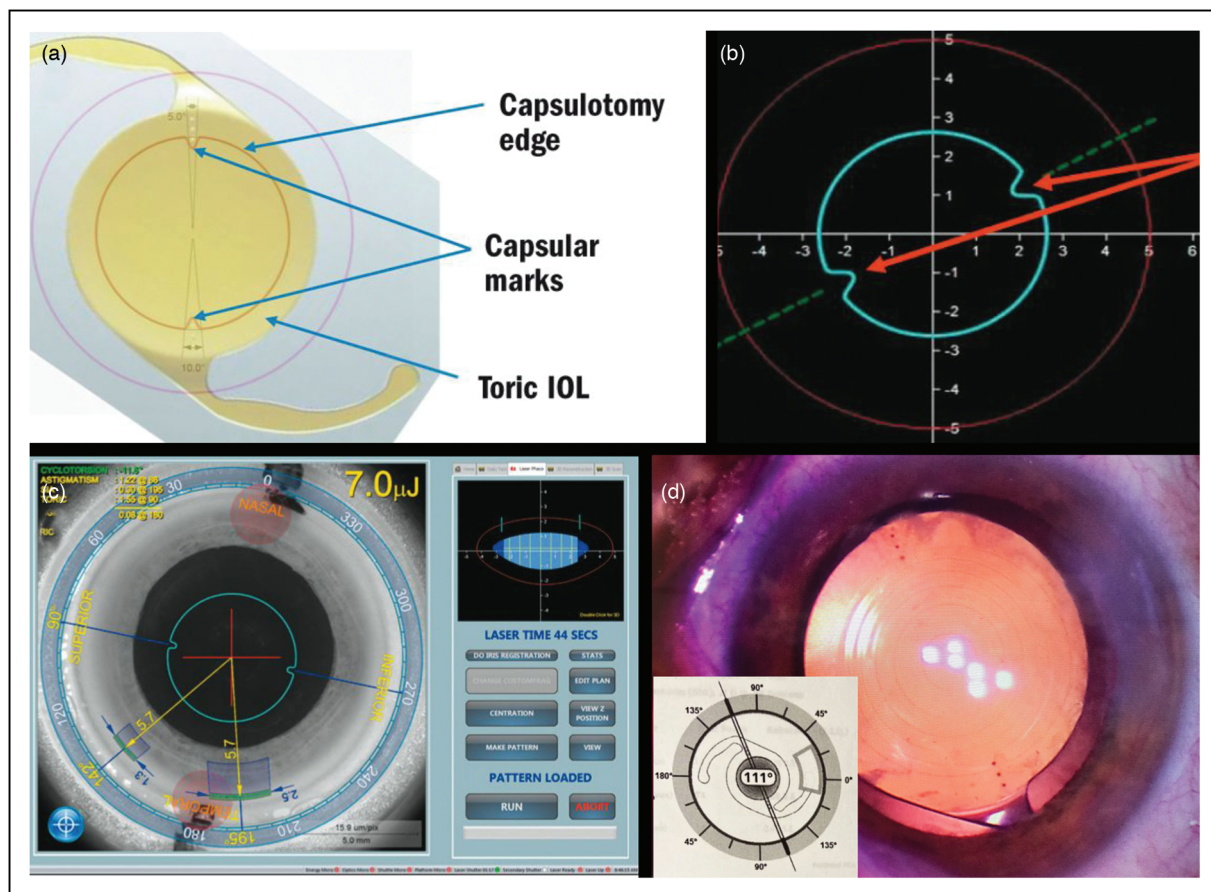
FLACS systems utilize intraoperative, and in some instances, preoperative imaging to guide incision and toric-lens positioning. Similar to most systems, the LENSAR femtosecond laser (LENSAR Inc., Orlando, FL, USA) utilizes intraoperative optical coherence tomograph imaging to recreate the anterior segment in three dimensions. The LENSAR system also enables integration of preoperative imaging including the Cassini Corneal Shape Analyzer (Cassini, The Hague, The Netherlands), the Corneal Analyzer OPD-Scan III (Nidek, Aichi, Japan), the Aladdin (Topcon Corporation, Tokyo, Japan), and both the Pentacam HR and the Pentacam AXL (Oculus, Wetzlar, Germany) to complement intraoperative measurements. With pre-registration of conjunctival vessels, the ARGOS Biometer enables full integration with the ALCON Cataract Refractive Suite, including LENSX Laser, VERION Image Guided System and the ORA SYSTEM technology. To achieve cohesion between preoperative and intraoperative measurements, the LENSAR system utilizes iris registration. This not only provides precise corneal incisions based upon available preoperative and intraoperative data but utilizing the LENSAR Streamline IV system, the capsulotomy is marked in two adjacent locations along the steep axis to enable precise toric IOL alignment (Fig. 3) [8<sup>1</sup>].

## SYNERGY OF FEMTOSECOND LASER-ASSISTED CATARACT SURGERY AND MULTIFOCAL/EXTENDED-DEPTH OF FOCUS INTRAOCULAR LENSES

Arguably one of the fastest advancing fields in ophthalmology is IOL design. Significant focus has been rightfully placed upon developing lenses that can provide spectacle independence due to multifocality. Outside of accommodative IOLs [23], these lens designs include refractive designs with varying refractive power zones and diffractive designs that divide light at diffraction grooves [24–26]. EDOF IOLs, create a continuum of foci rather than distinct focal points. Examples of these lenses available in both toric and nontoric varieties include the Acrysof IQ Vivity (Alcon Laboratories, Fort Worth, TX) and the TECNIS Symphony (Abbott Medical Optics, Santa Ana, CA). As compared with diffractive multifocal lenses, EDOF lenses are characterized by less halos and glare but do not provide the same range of vision from distance to near [24–26].

Groups have begun to use these EDOF lenses, in particular the Vivity lens, in a mini-mono or even monovision like format with the dominant eye set to distance – intermediate and the nondominant eye set to intermediate-near. Although early, the opinions of many surgeons to date suggest that staggering the focus of the mini-mono or mono staggering of Vivity lens 0.5 to 0.7 diopters apart can provide a full range of vision with minimal visual distortion. This technique of BLENDS, Bilateral Lens EDOF with Near Distance Staggering, appears extremely promising even in persons with ocular pathology including mild epiretinal membrane, glaucoma and foveal drusen. At this stage it remains unclear if this blended vision will prove intolerable to some patients in the same way standard monovision with monofocal lenses is intolerable. From these early reports, it does appear that the Vivity, similar to trifocal lenses, performs best with minimal astigmatism, supporting the synergism of pairing this lens with FLACS. In addition to EDOF lenses, a variety of trifocal lenses such as the AcrySof IQ PanOptix (Alcon Laboratories, Fort Worth, TX), the AT LISA tri 839MP (Carl Zeiss Meditec AG, Jena, Germany) and FineVision Micro F (PhysIOL, Liege, Belgium) have become commercially available. As compared with bifocal IOLs, diffractive trifocal IOLs offer improved intermediate visual acuity with equivalent distance and near visual acuity [27–35]. The trade-off for trifocal lenses is the photic visual phenomena, that is, glare and halos are increased [27–35].

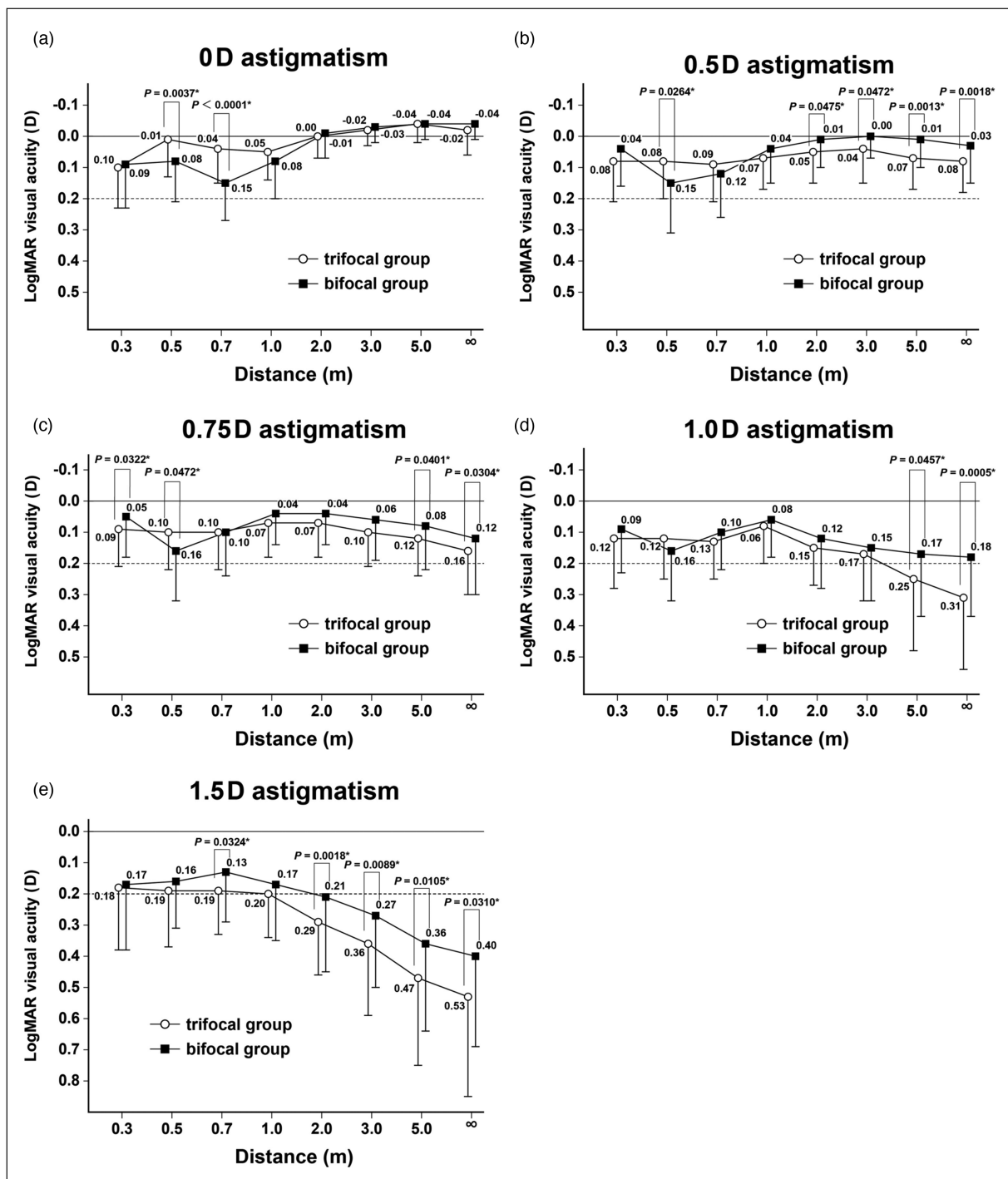
To maximize all distance visual acuities and reduce visual disturbances with multifocal lenses,



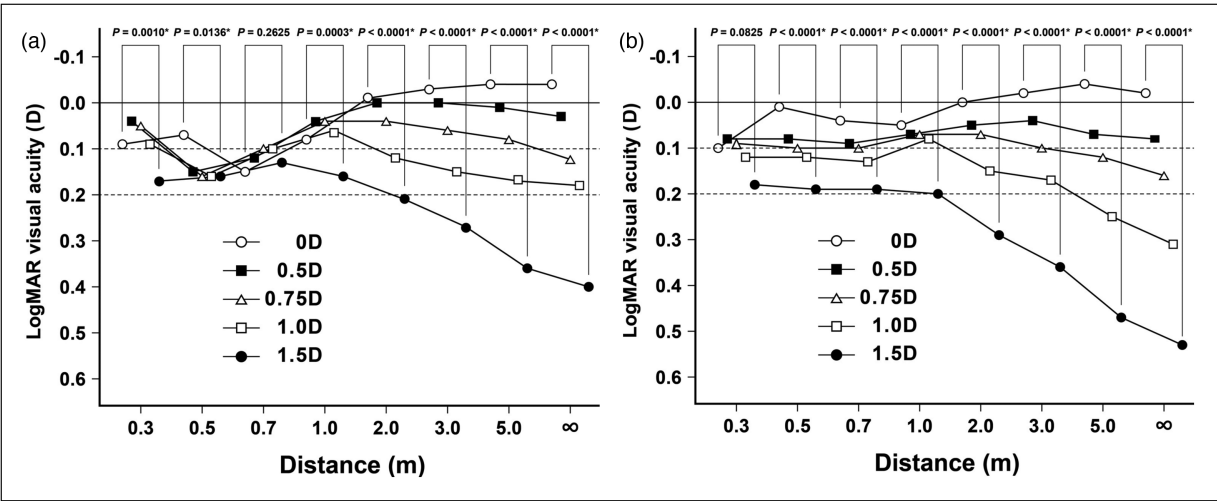
**FIGURE 3.** Femtosecond optimization of lens alignment. (a) Schematic diagram demonstrating the principle of LENSAR laser capsular marks for toric IOL alignment. (b) LENSAR laser capsulotomy with capsular marks to facilitate toric IOL alignment. (c) LENSAR Streamline IV with toric IOL marks for iris registration. (d) Intraoperative photograph with toric lens preop calculation inset, demonstrating precise alignment of the Panoptix trifocal IOL with use of the LENSAR laser capsulotomy at the desired axis with lens precisely centered in the visual axis based upon the light reflex (images courtesy of Mark Packer (a–c) and Dagny Zhu (d)). [8<sup>•</sup>].

it is becoming increasingly clear that postoperative astigmatism must be minimized [36<sup>•</sup>,37]. Accordingly, it makes intuitive sense that the introduction of multifocal IOLs was rapidly followed by multifocal toric and toric EDOF lenses. Studies of refractive bifocal IOLs demonstrated decreased uncorrected visual acuity with residual astigmatism more than 1 D [24,34]. The literature is replete with other examples of residual astigmatism, compromising uncorrected visual acuity with multifocal lens use [27–35,38<sup>••</sup>,39,40]. Not surprisingly, the use of toric multifocals achieved a level of satisfaction in patients previously untenable with nontoric multifocals [27–35]. Follow-up studies have clearly demonstrated that astigmatism correction for bifocal IOLs, either utilizing multifocal toric IOLs [41–44] or corneal relaxing incisions [45–48], improves outcomes for eyes with more than 1 D of astigmatism. For trifocal IOLs, it appears the field goal for target of postoperative residual astigmatism has been moved even further [36<sup>•</sup>,37].

Hayashi *et al.* [38<sup>••</sup>] showed that postoperative astigmatism compromises visual acuity, and in particular distance visual acuity, more in trifocal than bifocal IOLs (Figs. 4 and 5). To provide useful visual acuity at all distances, the residual astigmatism in the Hayashi study had to be 0.75 D or less (Figs. 4 and 5) [38<sup>••</sup>]. Taken together with previous studies, it is imperative that in the setting of trifocal IOLs, astigmatic correction via toric IOL [41,43–45,49] and/or corneal relaxing incisions should be performed [36<sup>•</sup>,37,45–48]. The results of the study from Hayashi [38<sup>••</sup>] on trifocal sensitivity to residual astigmatism makes intuitive sense, as the increased complexity of trifocal IOLs would act to amplify any light diffraction and HOA created by astigmatism [50<sup>•</sup>,51]. These findings are further supported by the work of Francesco Carones who induced variable levels of positive and negative cylinder in patients with four multifocal IOLs, including the Panoptix trifocal [52<sup>••</sup>]. In comparison to the ReSTOR 3.0,



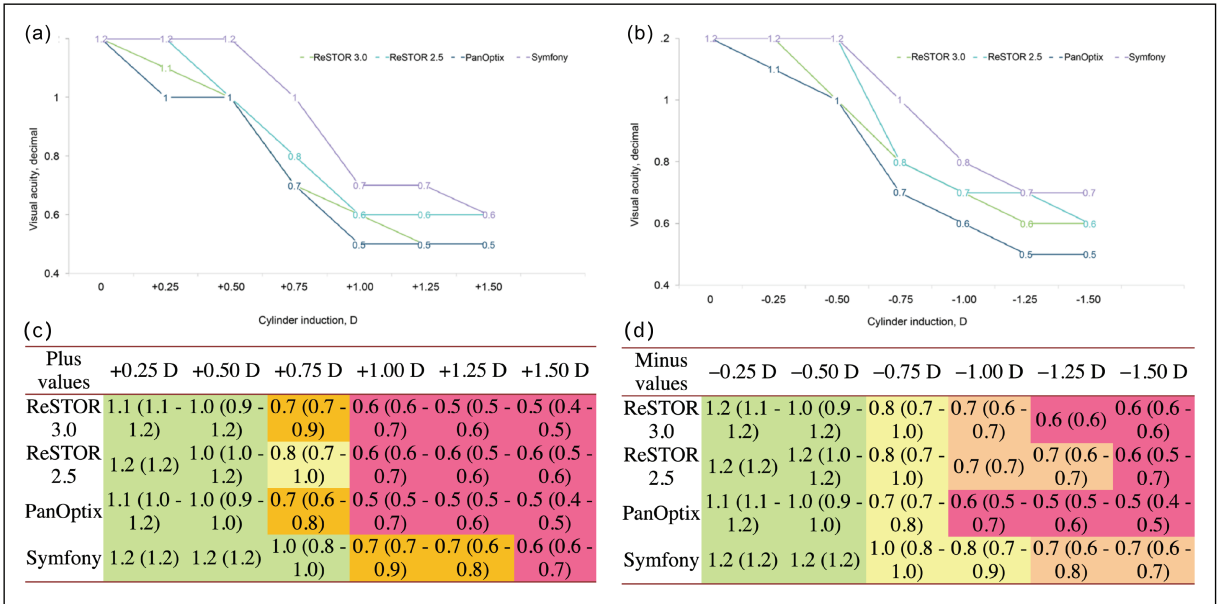
**FIGURE 4.** Comparison of the mean ( $\pm$ standard deviation) corrected logarithm of minimal angle of resolution visual acuity (logMAR visual acuity) from far to near distances between eyes implanted with a trifocal IOL (trifocal group) or a bifocal IOL (bifocal group). (a) No astigmatism (0D of astigmatism); mean intermediate logMAR visual acuity at 0.5 and 0.7 m was significantly better in the trifocal group than in the bifocal group, whereas visual acuity at the other distances did not differ significantly. (b) (0.5D of astigmatism) and (c) (0.75D of astigmatism); intermediate visual acuity at 0.5 m was significantly better in the trifocal group than in the bifocal group, whereas distance visual acuity at  $\infty$ , 5.0, 3.0, and 2.0 m was significantly worse in the trifocal group. (d) 1.0D of astigmatism; distance visual acuity at  $\infty$  and 5.0 m was significantly worse in the trifocal group, whereas visual acuity at other distances did not differ significantly between the groups. (e) 1.5D of astigmatism; distance visual acuity at  $\infty$ , 5.0, 3.0, and 2.0 m, and intermediate visual acuity at 0.7 m was significantly worse in the trifocal group than in the bifocal group. \*Statistically significant difference between the trifocal and bifocal groups [38\*\*].



**FIGURE 5.** (a) Changes in the mean corrected logarithm of minimal angle of resolution (logMAR) visual acuity from far to near distances caused by the diopters of added astigmatism in eyes implanted with a bifocal IOL. Mean corrected logMAR visual acuity worsened significantly in proportion to the added astigmatism at far, intermediate at 1.0 and 0.5 m, and near distances, whereas it did not differ significantly at the intermediate distance of 0.7 m. (b) Changes in the mean corrected logMAR visual acuity from far to near distances caused by D of added astigmatism in eyes implanted with a trifocal IOL. Mean corrected logMAR visual acuity significantly worsened in proportion to the added astigmatism at far to intermediate distances, whereas it did not differ significantly at a near distance of 0.3 m. Comparisons between each pair of added astigmatism revealed significant differences in the distance visual acuity at ∞, 5.0, 3.0, and 2.0 m between most pairs of added astigmatism. \*Statistically significant difference among the diopters of added astigmatism [38\*\*].

ReSTOR 2.5, and the Symphony lenses, patients with the PanOptix were the most susceptible to decline in visual acuity with induced cylinder (Fig. 6a and b). This visual decline was

accompanied by a concurrent reduction in patient satisfaction scores, that similarly, was most affected in the PanOptix trifocal IOL group [52\*\*] (Fig. 6c and d).



**FIGURE 6.** Mean visual acuity with four multifocal IOLs after the induction of different values of positive cylinder (a) and negative cylinder (b). Mean visual acuity and patient satisfaction scores with four multifocal IOLs after the induction of different values of positive cylinder (c) and negative cylinder (d) (green = very satisfied; yellow = moderately satisfied; orange = not satisfied; red = not at all satisfied). Values are reported as median, with range in brackets [52\*\*].



## CONCLUSION

The synergistic combination of multifocal/EDOF IOLs with FLACS is an extremely promising route in achieving postoperative spectacle independence for patients (Fig. 6). By incorporating intraoperative and preoperative imaging, femtosecond platforms, such as those that utilize iris registration, can enable a precision of corneal incisions and toric IOL markings that enable the lowest possible postoperative levels of astigmatism. Current studies suggest that with increasing IOL complexity, that is, trifocal versus bifocal, image degradation with even low levels of postoperative astigmatism are increased. To this end, current data support the utility of femtosecond laser arcuate incisions to enable the achievement of 0.5 D or less postoperative astigmatism for best outcomes with multifocal lenses. The marriage of the precision of FLACS with the increasing complexity of multifocal/EDOF IOLs will fuel nomogram adjustment and systematic improvements, such as the Wörtz–Gupta formula, that provide an unprecedented deliberate precision to cataract surgery. Although early, promising results of femtosecond adjusted IOLs may further enable postoperative touch-ups to a multifocal or precise optical modification of a previously monofocal IOL that will allow multifocal optics to be generated that are wholly customized to each eye. The synergy of femtosecond laser and multifocal IOLs shows increasing promise in enabling FOCUSED (Femtosecond Optimized Continuous Uncorrected Sight with EDOF and Diffractive multifocal IOLs).

## Acknowledgements

None.

## Financial support and sponsorship

*This study received unrestricted grant from Research to Prevent Blindness, New York, NY.*

## Conflicts of interest

*There are no conflicts of interest.*

## REFERENCES AND RECOMMENDED READING

Papers of particular interest, published within the annual period of review, have been highlighted as:

- of special interest
- of outstanding interest

1. Ferrer-Blasco T, Montes-Mico R, Peixoto-de-Matos SC, *et al.* Prevalence of corneal astigmatism before cataract surgery. *J Cataract Refract Surg* 2009; 35:70–75.
  2. Byun YS, Kim S, Lazo MZ, *et al.* Astigmatic correction by intrastromal astigmatic keratotomy during femtosecond laser-assisted cataract surgery: factors in outcomes. *J Cataract Refract Surg* 2018; 44:202–208.
  3. Kessel L, Andresen J, Tendal B, *et al.* Toric intraocular lenses in the correction of astigmatism during cataract surgery: a systematic review and meta-analysis. *Ophthalmology* 2016; 123:275–286.
  4. Ruckl T, Dexl AK, Bacherneegg A, *et al.* Femtosecond laser-assisted intrastromal arcuate keratotomy to reduce corneal astigmatism. *J Cataract Refract Surg* 2013; 39:528–538.
  5. Hayashi K, Sato T, Igarashi C, Yoshida M. Effect of spherical equivalent error on visual acuity at various distances in eyes with a trifocal intraocular lens. *J Refract Surg* 2019; 35:274–279.
- Following trifocal IOL implantation, a manifest spherical equivalent error of slight myopia significantly improved near visual acuity but worsened distance visual acuity, whereas that of slight hyperopia worsened both distance and near visual acuity.
6. Wolffsohn JS, Bhogal G, Shah S. Effect of uncorrected astigmatism on vision. *J Cataract Refract Surg* 2011; 37:454–460.
  7. Vitale S, Ellwein L, Cotch MF, *et al.* Prevalence of refractive error in the United States, 1999–2004. *Arch Ophthalmol* 2008; 126:1111–1119.
  8. Teuma EV, Gray G, Bedi R, Packer M. Femtosecond laser-assisted capsulotomy with capsular marks for toric IOL alignment: comparison of tensile strength with standard femtosecond laser capsulotomy. Femtosecond laser-assisted arcuate keratotomy at the time of cataract surgery for the management of preexisting astigmatism. *J Cataract Refract Surg* 2019; 45:1177–1182.
- Femtosecond laser arcuate incisions combined with toric alignment capsulotomy represents a safe and effective method for astigmatism correction at the time of cataract surgery.
9. Chan TC, Cheng GP, Wang Z, *et al.* Vector analysis of corneal astigmatism after combined femtosecond-assisted phacoemulsification and arcuate keratotomy. *Am J Ophthalmol* 2015; 160:250–255.e2.
  10. Harissi-Dagher M, Azar DT. Femtosecond laser astigmatic keratotomy for postkeratoplasty astigmatism. *Can J Ophthalmol* 2008; 43:367–369.
  11. Nubile M, Carpineto P, Lanzini M, *et al.* Femtosecond laser arcuate keratotomy for the correction of high astigmatism after keratoplasty. *Ophthalmology* 2009; 116:1083–1092.
  12. Wetterstrand O, Holopainen JM, Krootila K. Treatment of postoperative keratoplasty astigmatism using femtosecond laser-assisted intrastromal relaxing incisions. *J Refract Surg* 2013; 29:378–382.
  13. Nejima R, Terada Y, Mori Y, *et al.* Clinical utility of femtosecond laser-assisted astigmatic keratotomy after cataract surgery. *Jpn J Ophthalmol* 2015; 59:209–215.
  14. Yoo A, Yun S, Kim JY, *et al.* Femtosecond laser-assisted arcuate keratotomy versus toric IOL implantation for correcting astigmatism. *J Refract Surg* 2015; 31:574–578.
  15. St Clair RM, Sharma A, Huang D, *et al.* Development of a nomogram for femtosecond laser astigmatic keratotomy for astigmatism after keratoplasty. *J Cataract Refract Surg* 2016; 42:556–562.
  16. Day AC, Lau NM, Stevens JD. Nonpenetrating femtosecond laser intrastromal astigmatic keratotomy in eyes having cataract surgery. *J Cataract Refract Surg* 2016; 42:102–109.
  17. Chan TC, Ng AL, Wang Z, *et al.* Five-year changes in corneal astigmatism after combined femtosecond-assisted phacoemulsification and arcuate keratotomy. *Am J Ophthalmol* 2020; 217:232–239.
- Eyes with femtosecond laser arcuate incisions examined over a five year period revealed overall stability with a tendency of increasing overcorrection of preoperative with the rule and undercorrection of against the rule of astigmatism over time.
18. Chan TC, Ng AL, Cheng GP, *et al.* Corneal astigmatism and aberrations after combined femtosecond-assisted phacoemulsification and arcuate keratotomy: two-year results. *Am J Ophthalmol* 2016; 170:83–90.
  19. Vickers LA, Gupta PK. Femtosecond laser-assisted keratotomy. *Curr Opin Ophthalmol* 2016; 27:277–284.
  20. Wörtz G, Gupta PK, Goernert P, *et al.* Outcomes of femtosecond laser arcuate incisions in the treatment of low corneal astigmatism. *Clin Ophthalmol* 2020; 14:2229–2236.
- The Wörtz–Gupta formula provides a means of preoperative planning for laser arcuate incisions in patients with low corneal astigmatism (<1.0 D) that improves all-distance visual acuity with multifocal IOLs.
21. Novis C. Astigmatism and toric intraocular lenses. *Curr Opin Ophthalmol* 2000; 11:47–50.
  22. Motwani M. The use of WaveLight(R) Contoura to create a uniform cornea: the LYRA Protocol. Part 3: the results of 50 treated eyes. *Clin Ophthalmol* 2017; 11:915–921.
  23. Palikaris IG, Kontadakis GA, Portaliou DM. Real and pseudoaccommodation in accommodative lenses. *J Ophthalmol* 2011; 2011:284961.
  24. Davison JA, Simpson MJ. History and development of the apodized diffractive intraocular lens. *J Cataract Refract Surg* 2006; 32:849–858.
  25. Portney V. Light distribution in diffractive multifocal optics and its optimization. *J Cataract Refract Surg* 2011; 37:2053–2059.
  26. Hertenstein H, Bach M, Gross NJ, Beisse F. Marked dissociation of photopic and mesopic contrast sensitivity even in normal observers. *Graefes Arch Clin Exp Ophthalmol* 2016; 254:373–384.
  27. Jonker SM, Bauer NJ, Makhotkina NY, *et al.* Comparison of a trifocal intraocular lens with a +3.0 D bifocal IOL: results of a prospective randomized clinical trial. *J Cataract Refract Surg* 2015; 41:1631–1640.
  28. Gundersen KG, Potvin R. Comparison of visual outcomes and subjective visual quality after bilateral implantation of a diffractive trifocal intraocular lens and blended implantation of apodized diffractive bifocal intraocular lenses. *Clin Ophthalmol* 2016; 10:805–811.

29. Bilbao-Calabuig R, Gonzalez-Lopez F, Amparo F, *et al.* Comparison between mix-and-match implantation of bifocal intraocular lenses and bilateral implantation of trifocal intraocular lenses. *J Refract Surg* 2016; 32:659–663.
30. Vilar C, Hida WT, de Medeiros AL, *et al.* Comparison between bilateral implantation of a trifocal intraocular lens and blended implantation of two bifocal intraocular lenses. *Clin Ophthalmol* 2017; 11:1393–1397.
31. de Medeiros AL, de Araujo Rolim AG, Motta AF, *et al.* Comparison of visual outcomes after bilateral implantation of a diffractive trifocal intraocular lens and blended implantation of an extended depth of focus intraocular lens with a diffractive bifocal intraocular lens. *Clin Ophthalmol* 2017; 11:1911–1916.
32. Kaymak H, Breyer D, Alio JL, Cochener B. Visual performance with bifocal and trifocal diffractive intraocular lenses: a prospective three-armed randomized multicenter clinical trial. *J Refract Surg* 2017; 33:655–662.
33. Shen Z, Lin Y, Zhu Y, *et al.* Clinical comparison of patient outcomes following implantation of trifocal or bifocal intraocular lenses: a systematic review and meta-analysis. *Sci Rep* 2017; 7:45337.
34. Ravalico G, Parentin F, Baccara F. Effect of astigmatism on multifocal intraocular lenses. *J Cataract Refract Surg* 1999; 25:804–807.
35. Dick HB, Krummenauer F, Schwenn O, *et al.* Objective and subjective evaluation of photic phenomena after monofocal and multifocal intraocular lens implantation. *Ophthalmology* 1999; 106:1878–1886.
36. Ludeke I, Gonnermann J, Jorgensen J, *et al.* Refractive outcomes of femtosecond laser-assisted secondary arcuate incisions in patients with residual refractive astigmatism after trifocal intraocular lens implantations. *J Cataract Refract Surg* 2019; 45:28–34.
- Femtosecond laser arcuate incisions safely and effectively reduce postoperative astigmatism in the setting of trifocal IOL implantation.
37. Xue S, Zhao G, Yin X, *et al.* Effect of incision on visual outcomes after implantation of a trifocal diffractive IOL. *BMC Ophthalmol* 2018; 18:171.
38. Hayashi K, Yoshida M, Igarashi C, Hirata A. Effect of refractive astigmatism on all-distance visual acuity in eyes with a trifocal intraocular lens. *Am J Ophthalmol* 2020.
- All-distance visual acuity was compromised more in trifocal than bifocal IOL in the setting of residual astigmatism. Achieving more than 0.75 D or less of residual astigmatism is critical for postoperative visual outcomes with trifocal IOLs.
39. Hayashi K, Hayashi H, Nakao F, Hayashi F. Influence of astigmatism on multifocal and monofocal intraocular lenses. *Am J Ophthalmol* 2000; 130:477–482.
40. Berdahl JP, Hardten DR, Kramer BA, Potvin R. Effect of astigmatism on visual acuity after multifocal versus monofocal intraocular lens implantation. *J Cataract Refract Surg* 2018; 44:1192–1197.
41. Visser N, Nuijts RM, de Vries NE, Bauer NJ. Visual outcomes and patient satisfaction after cataract surgery with toric multifocal intraocular lens implantation. *J Cataract Refract Surg* 2011; 37:2034–2042.
42. Alio JL, Pinero DP, Tomas J, Aleson A. Vector analysis of astigmatic changes after cataract surgery with toric intraocular lens implantation. *J Cataract Refract Surg* 2011; 37:1038–1049.
43. Kretz FT, Bastelica A, Carreras H, *et al.* Clinical outcomes and surgeon assessment after implantation of a new diffractive multifocal toric intraocular lens. *Br J Ophthalmol* 2015; 99:405–411.
44. Alfonso JF, Knorz M, Fernandez-Vega L, *et al.* Clinical outcomes after bilateral implantation of an apodized +3.0 D toric diffractive multifocal intraocular lens. *J Cataract Refract Surg* 2014; 40:51–59.
45. Gangwani V, Hirschschall N, Findl O, Maurino V. Multifocal toric intraocular lenses versus multifocal intraocular lenses combined with peripheral corneal relaxing incisions to correct moderate astigmatism. *J Cataract Refract Surg* 2014; 40:1625–1632.
46. Fouda S, Kamiya K, Aizawa D, Shimizu K. Limbal relaxing incision during cataract extraction versus photoastigmatic keratectomy after cataract extraction in controlling preexisting corneal astigmatism. *Graefes Arch Clin Exp Ophthalmol* 2010; 248:1029–1035.
47. Mendicute J, Irigoyen C, Ruiz M, *et al.* Toric intraocular lens versus opposite clear corneal incisions to correct astigmatism in eyes having cataract surgery. *J Cataract Refract Surg* 2009; 35:451–458.
48. Löffler F, Böhm M, Herzog M, *et al.* Tomographic analysis of anterior and posterior and total corneal refractive power changes after femtosecond laser-assisted keratotomy. *Am J Ophthalmol* 2017; 180:102–109.
49. Alio JL, Pinero DP, Tomas J, Plaza AB. Vector analysis of astigmatic changes after cataract surgery with implantation of a new toric multifocal intraocular lens. *J Cataract Refract Surg* 2011; 37:1217–1229.
50. Kohnen T, Suryakumar R. Extended depth-of-focus technology in intraocular lenses. *J Cataract Refract Surg* 2020; 46:298–304.
- A review of four emerging extended depth of focus IOLs including the small aperture, bioanalogic, diffractive optics, and nondiffractive optical IOLs.
51. Kohnen T, Herzog M, Hemkeppeler E, *et al.* Visual performance of a quadrifocal (trifocal) intraocular lens following removal of the crystalline lens. *Am J Ophthalmol* 2017; 184:52–62.
52. Carones F. Residual astigmatism threshold and patient satisfaction with bifocal, trifocal and extended range of vision intraocular lenses (IOLs). *Open J Ophthalmol* 2017; 7:1–7.
- Variable levels of positive and negative-induced cylinder results in decline in visual acuity and patient satisfaction that is more significant in trifocal than bifocal and EDOF IOLs.